


PRESENTING CLINICAL SIGNS

DATE History: Murmur. Pre-anesthetic evaluation. Receiving pimobendan 0.625 mg BID.

5/4/22 **ECHOCARDIOGRAPHIC FINDINGS**

2D, M-mode, and Doppler study.

PERFORMED BY: There is mild left atrial dilation. The mitral valve leaflets are thickened and exhibit systolic prolapse. There is Doppler evidence of mitral regurgitation present. There is mild left ventricular dilation. Left ventricular systolic function is mildly hyperdynamic. The aorta and aortic valve appear normal, though trace aortic insufficiency is present. Right atrial and right ventricular dimensions are normal. The tricuspid valve leaflets are mildly thickened, and there is Doppler evidence of tricuspid regurgitation present. TR velocity does not suggest the presence of pulmonary hypertension. The pulmonary artery and pulmonic valve are normal. No shunting lesions are visualized. No pericardial effusion or cardiac masses are seen.

Dr. Meredith Swart

INTERPRETED BY

Keith Blass, DVM,
MS, DACVIM
(Cardiology)

PATIENT
Lollipop Snoke

SPECIES
Canine

LA - 21.6 mm
LVIDd - 22.9 mm
LVIDs - 12.8 mm
FS - 44%
RA - 16.9 mm
LVOT - 1.33 m/s
RVOT - 0.83 m/s
TR - 2.69 m/s

ASSESSMENT/RECOMMENDATIONS

Degenerative mitral and tricuspid valve disease

BREED This examination demonstrates regurgitation of blood across Lollipop's mitral and tricuspid valves resulting from degenerative valve disease. Lollipop's tricuspid valve disease is mild, and appears to be well-compensated at this time. Her mitral valve disease is a bit more advanced, as Lollipop has mild secondary dilation of both her left atrium and left ventricle, though her left ventricular systolic function is well-preserved. As only mild left heart chamber dilation is present, Lollipop's mitral valve disease appears to be well-compensated, and her current risk for the development of clinical signs secondary to it, such as coughing, exercise intolerance, syncope, and labored breathing, appears to be relatively low.

Chihuahua Mix

SEX

FS

AGE Lollipop's cardiovascular risk for general anesthesia is mildly increased based on this exam, therefore, precautions should be taken in order to minimize this risk. I recommend avoiding the use of alpha-2 agonists, ketamine, and telazol in the anesthetic protocol, as well as reducing the IV fluid rate by 25%. If possible, monitoring of heart rhythm, blood pressure, and pulse oximetry are recommended during the procedure.

11 y

WEIGHT Continued use of pimobendan is warranted based on this exam, though I recommend increasing Lollipop's dose to 1.25 mg am and 0.625 mg pm.

6.7 lb

HOSPITAL NAME A recheck echocardiogram is recommended in 9 months. Thoracic radiographs are recommended if Lollipop experiences respiratory clinical signs.

Swart Veterinary
Imaging

REFERRING VET

Dr. Swart



Im: 7/32
Se: 1

Swart Veterinary Imaging
05/04/22 03:12:00PM ADM

SNOKE, LOLLIPOP
20-13686SNOKE

MI 1.2 TIs 0.4 SNOKE LOLLIPOP
20-13686SNOKE
SMI 1.580
6/5/2010 F

Swart Veterinary Imaging
-AO% 100

- CHI
Frq 7.0
Gn 53
D 6.0

- CF
2-Frq 3.0
Gn 16.5
L/A 2/4
PRF 5.1
WF 586
S/P 3/10

65
-65 cm/s

R LAX MV

GE

WL: 128 WW: 256 [D]

5/4/2022 3:08:06 PM

DATE

5/4/22

PERFORMED BY:

Dr. Meredith Swart

INTERPRETED BY

Keith Blass, DVM,
MS, DACVIM
(Cardiology)

PATIENT

Lollipop Snoke

SPECIES

Canine

BREED

Chihuahua Mix

SEX

FS

AGE

11 y

WEIGHT

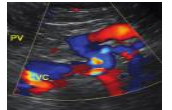
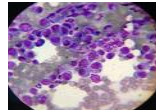
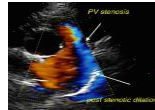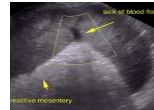6.7 lb

HOSPITAL NAME

Swart Veterinary
Imaging

REFERRING VET

Dr. Swart



DATE

5/4/22

The information and recommendations provided are based on the images presented by the referring veterinarian. No evaluation can be communicated regarding pathology that was not visible in the image/video clips provided.

Thank you for this referral. If the clinical or image interpretation does not parallel your findings or if I can be of any further assistance please contact me.

PERFORMED BY:

Dr. Meredith Swart

Keith Blass, DVM, MS, DACVIM (Cardiology)
KeithBlass@gmail.com
631-804-5754

INTERPRETED BY

Keith Blass, DVM,
MS, DACVIM
(Cardiology)

PATIENT

Lollipop Snoke

SPECIES

Canine

BREED

Chihuahua Mix

SEX

FS

AGE

11 y

WEIGHT

6.7 lb

HOSPITAL NAME

Swart Veterinary
Imaging

REFERRING VET

Dr. Swart